



# OCT Angiography: The Newest Frontier for the Revolutionary Technology

OCT Angiography is a new non-invasive, motion contrast micro-vascular imaging modality. Based on two patented primary technologies, Split Spectrum Amplitude Decorrelation Angiography (SSADA) and Motion Correction Technology (MCT), Optovue launched the first OCT Angiography system, AngioVue, at the XXXII Congress of the ESCRS in London in 2014. Worldwide, ophthalmologists have started using it clinically and are reporting on the early experience with this evolutionary technology



# The AngioVue Difference

By Tony Ko, PhD



Optovue has developed a new way of visualizing vessels that allows clinicians to identify retinal circulation using the intrinsic motion of the blood cells in the vessel with non-invasive microvascular enhanced imaging. These devices use optical coherence tomography-angiography (OCT-A), and are by far the most advanced imaging products to date.

The AngioVue Imaging System is not like traditional OCT. It acquires function rather than structural information. This system is also very different from traditional angiography such as fluorescein angiography or ICAG since it does not require contrast dye injection that can be difficult to accomplish on some patients.

## Differentiating features

The AngioVue Imaging System can acquire different scan sizes in the macula and the optic disc in about 3 seconds. Two imaging volumes are acquired in sequence in order to later perform motion correction to remove the saccadic artifacts.

Segmentations are automatically generated to identify the circulatory layers of interest, such as the superficial capillary and the deep capillary in the macula. Figure 1 illustrates the AngioVue Imaging System's capabilities in a normal macula. The left image shows a 304x304 pixel image, and this is at the level of the superficial capillary. Unlike traditional angiography techniques, the depth-resolved capability of the AngioVue Imaging System allow specific layers of the retina to be isolated with a clarity never before seen. With this type of enhanced imaging, clinicians are going to be able to detect miniscule changes more rapidly, possibly identifying diseases at earlier stages.

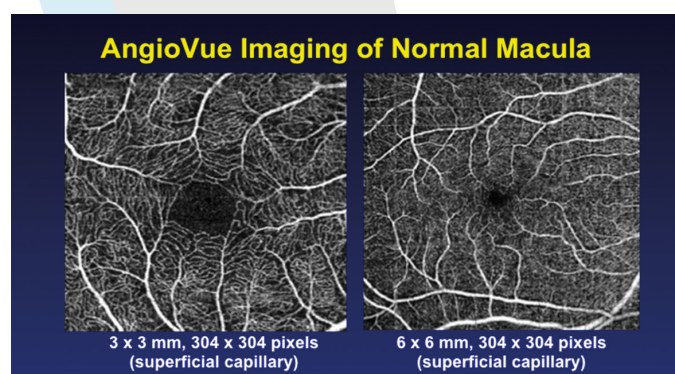


Figure 1. Angioflow images on the AngioVue Imaging System of a normal macula

## Details on the design: platform

Optovue used its high-speed SD-OCT imaging system, the Avanti, as the platform to build the AngioVue Imaging System. We wanted to ensure clinicians were familiar with the technology to minimize the learning curves where possible and for easy implementation into practice flow and patient management.

## Details on the design: motion contrast

Split-Spectrum Amplitude-Decorrelation Angiography, or SSADA, was developed by David Huang, MD, PhD, of the Center for Ophthalmic Optics & Lasers (COOL) at the Casey Eye Institute in Portland, Ore. This algorithm takes sequential consecutive OCT scans, and then compares each OCT scan with the subsequent scan. The SSADA algorithm also uses multiple spectrums from single B-scan to improve the image quality. Therefore, it reduces the number of repeat B-scans required for achieving good vascular imaging. Because of SSADA algorithm, the AngioVue image system can achieve high quality vascular images with lower acquisition times.

By looking at the changes in the pixel intensity at a particular location, we can generate a decorrelation value, a marker of whether there's motion or not, which in this case would be either flow in the vessel or static tissue. The SSADA algorithm then generates a flow image, or a functional image of this B-scan. And by taking a large number of B-scans we can generate a 3-D volume of retinal vasculature on the AngioVue Imaging System.

This SSADA algorithm offers the highest quality OCT-Angiography images available today. Figure 2 illustrates how the SSADA processing enhances the imaging data. The two images are generated from the same data set, but the one on the right used the SSADA technology to achieve higher signal-to-noise ratio and better visualization of the vasculature.

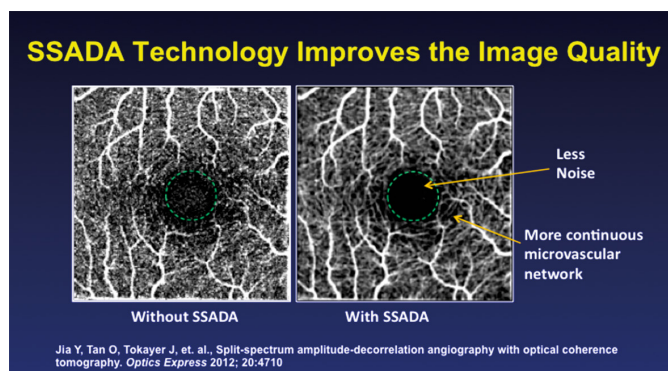


Figure 2. SSADA on the AngioVue Imaging System provides less noise than typical OCT Angiography techniques

## Details on the design: en face visualization

En face visualization is based on the retina anatomy. Because this is an OCT based technique, we can use the OCT data to perform segmentation on the layers of interest in the eye, and we can generate en face visualization of the vessels at different layers of anatomic interest, such as the superficial capillary and the deep capillary and the choroidal capillary.

## Details on the design: motion correction

The idea behind motion correction is very simple, by acquiring two complementary datasets sequentially, unavoidable



saccadic artifacts can be removed afterwards using sophisticated motion correction algorithm. This technique was initially developed in academic labs where the motion correction processing time can take up to 5 to 10 minutes to complete. We used a parallel computing platform to cut the processing time down to less than 10 seconds. This makes the motion correction technology in the AngioVue Imaging System feasible in a clinical setting.

## In conclusion

Figure 3 shows a fibrovascular pigment epithelial defect (PED), where we have OCT B-scans on the bottom and on the right, and the OCT en face in the middle, and the Angioflow image on the top left. Using the AngioVue Imaging System, we imaged the layer underneath the retinal pigment epithelial to generate the image of the fibrovascular PED. These are vessels that are extremely difficult to image on fluorescein angiography because they are so leaky and hyperfluorescent. Yet the Angioflow images presents an extremely clear visualization of the vessels underneath all that leakage.

The AngioVue Imaging System is a breakthrough technology which provides both structural and functional image of retina

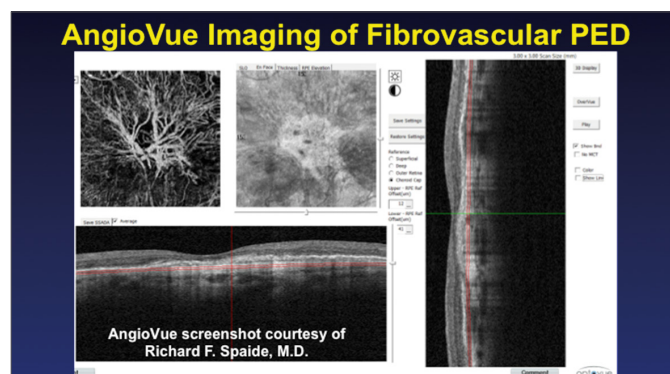


Figure 3. Angioflow images of fibrovascular pigment epithelial defect

tissue. It is a fast and high resolution system which can image even the most difficult patients in a busy clinic office.

*Tony Ko is the Vice President of Research and Development for Optovue, Inc. Tony received his Ph.D. in Medical Engineering from the Massachusetts Institute of Technology and has over 15 years of experience in OCT research*

# AngioVue Imaging System: The Future of Imaging?

*After evaluating this system, the answer is mostly likely 'yes'*

By Bruno Lumbroso, MD



**T**he AngioVue Imaging System (Optovue) is going to drastically alter how retina specialists think about imaging. I have personally used the device for a little more than 12 months and to say I've been impressed is an understatement.

In my experience, OCT angiography has added several new possibilities to my practice, to complement the information I gather from fluorescein angiography (FA). It is important to understand how the information gathered from the Angioflow images differs from information gathered from FA, and provides an important additional diagnostic device to your armamentarium.

First, FA uses a dye to record the vascular network, whereas the AngioVue Imaging System uses the movement of blood cells in the vessels. FA needs to be scheduled. Angioflow images can be taken in a few minutes, and the technique is fast and easy. I've found it fits well into an everyday, typical patient work-up and does not require invasive dye injections that could lead to side effects.

However, all of this would be irrelevant if the data we're getting from the AngioVue Imaging System were not at least as good as what we're used to seeing on FA. Here are some of my key evolving clinical applications that should help to demonstrate the quality of the data that we are acquiring from these Angioflow images.

Because OCT Angiography images do not use a dye, there's no leakage. Blood flow remains inside the vessels.




Figure 1. Capillary abnormalities as viewed by two different systems  
The figure on the left uses the AngioVue Imaging System to view the capillary abnormalities while the topography map (figure on right) confirms that there is obvious edema corresponding to the capillary disorder

That allows us to highlight capillary abnormalities much better than we could with FA (see Figure 1).

One of my primary caveats—do not expect to consistently obtain good images with the device out of the box. There is an initial learning curve with this Non-Invasive Microvascular Enhanced Imaging technology platform. Any good retina specialist will be surprised when they view their first few images: there's no leakage, no staining or pooling, and the images can seem "too sharp" or "too dry." Figure 2a illustrates vascular circulation with AngioVue Imaging System; figure 2b shows the same eye, imaged with FA instead. Fluorescein staining gives the




Figure 2a. Angioflow image

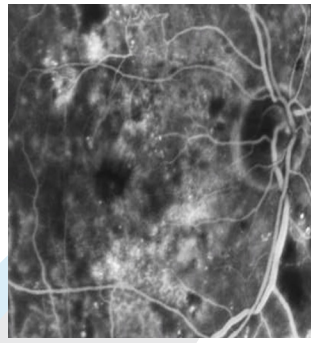


Figure 2b. Fluorescein angiography

Figures 2a/2b. Angioflow images on the AngioVue Imaging System offer a much cleaner and sharper image (a) than fluorescein angiography (b)

impression the vessels are larger, and makes it a bit more difficult to understand the blood circulation. OCT Angiography shows the vessel contents and does not show their walls.

### Deeper disease imagery

This technology has several advantages in research applications, as it can easily image each retinal layer separately and allow us to study flow area. In cases of choroidal neovascularization in age-related macular degeneration, the afferent core vessels and peripheral anastomoses can be seen clearly with Angioflow images (Figure 3), whereas fluorescein leaks too much to see the structures as distinctly. Choroidal neovascularities are much crisper when using Angioflow images in lieu of FA.




Figure 3. The choroidal neovascularization net

### In real-world settings

In age-related macular degeneration, choroidal neovascularization is typically seen as a sharp vascular net, one that is not blurred by dry leakage. What we often find in our images are the afferent vessel and the peripheral anastomoses. Yet 24 hours after an anti-vascular endothelial growth factor intravitreal injection, the network

is visibly smaller with fewer anastomoses. Flow changes produced a fragmented aspect of the network. Secondary branches decreased or disappear entirely post-injection. The presumption is that flow decreased inside the capillaries. What I personally found most interesting, however, is that these same branches re-appear and by Day 30 are almost at their baseline levels. In my opinion, that would reconfirm the recommendation for monthly dosing in that particular patient. Each time this patient was injected, the secondary branches would disappear for 7 to 20 days (as confirmed on the Angioflow images), but would reappear almost 30 days after the anti-VEGF injection.

If our observations are confirmed by large studies, this new diagnostic tool will allow us to customize and personalize treatment. It may lead one day to determine why some cases might need monthly injections while some other does not.

### Branch retinal vein occlusion

Figures 4 (Angioflow) and 5 (FA) show a patient with upper temporal venous branch occlusion, where OCT Angiography of the occluded branch shows a rarefaction of the deep vascular plexus. Images were taken over the course of 2 months.




Figure 4. Using the AngioVue Imaging System in BRVO (temporal venous branch occlusion)

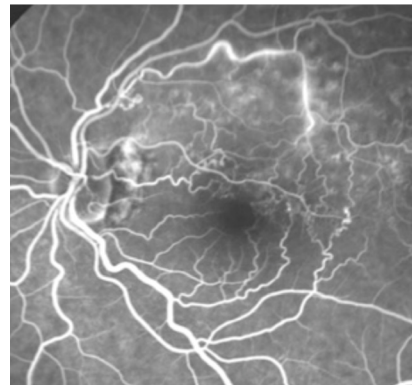


Figure 5. Using FA to image upper temporal venous branch occlusion. Same case as in Figure 4

This technology provides clinicians with new useful information that is less expensive to administer than current imaging modalities, and that has fewer side effects. In short, Angioflow images on the AngioVue Imaging System may be the future of retinal imaging.

Dr. Lumbroso is Director, Centro Oftalmologico Mediterraneo for Retinal Diseases, Rome, and is the General Secretary of the Italian Laser Society. He may be reached at [bruno.lumbroso@gmail.com](mailto:bruno.lumbroso@gmail.com)



# Choroidal Visualization Using a Non-Invasive Microvascular Enhanced Imaging Platform

*The latest stepwise improvement in imaging on the AngioVue Imaging System allows us to see aspects of the retina with clarity never before imagined*



By Giovanni Staurenghi, MD

**F**irst and foremost, I believe OCT angiography is the next step in imaging. I love angiography—I use both fluorescein and ICG often in my practice. I have, and will probably remain, a multimodality imaging supporter. The AngioVue Imaging System (Optovue) is the one device I've used that may make me reduce the amount of imaging I do with my beloved angiography.

Here's why: OCT and the AngioVue Imaging System is yet another stepwise improvement in our ability to image those structures we need to see to correctly diagnose retinal disease.

To visualize the choroid, we need to perform ICG angiography. When we inject the dye, and then follow it carefully, we begin to see the Haller layer, the Sattler layer, and even the choriocapillaris. Or, at least we can visualize the idea of the choriocapillaris – we know that imaging this structure has always been a challenge because of the highly pigmented choroidal melanocytes and the location (below the retinal pigment epithelial layer). See Figure 1. In cases of geographic atrophy, what we're imaging is the edge between a presence or absence of choriocapillary.

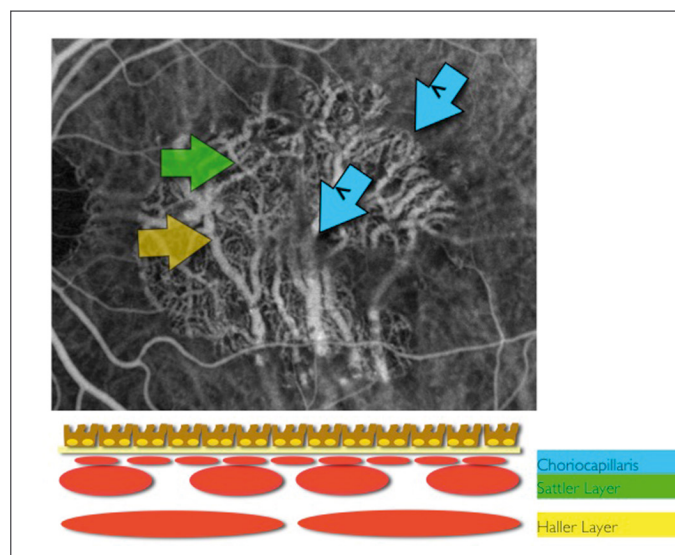


Figure 1. Imaging the choriocapillaris, Sattler layer, and Haller layer

Today's retina specialist has a wide choice of imaging devices from which to choose, and each has its own unique advantages. They can all help identify and image the choroid. Enhanced depth imaging using spectral-domain OCT was what truly moved the field ahead, in my opinion. These devices allowed us to determine the different characteristics of a choroid in normal subjects, making it easier to differentiate those with disease. However, there remained a great deal of variability, especially in terms of thickness.

Another way to image the choroid is to use en face modality, introduced by Optovue, and Prof. Lumbroso was a big proponent of the technology. As defined, "En face OCT angiograms of the choriocapillaris and choroidal vasculature are visualized by acquiring cross-sectional OCT angiograms volumetrically via raster scanning and segmenting the three-dimensional angiographic data at multiple depths below the retinal pigment epithelium (RPE)." <sup>1</sup>

But even with OCT and en face imaging, we still don't see the flow, just the shadows of the vessels. But we can detect choroidal neovascularization (CNV), and differentiate the normal choroidal vessels from where the CNV resides. By overlapping an ICG image, the structures of the retinal vasculature become apparent (see Figure 2).

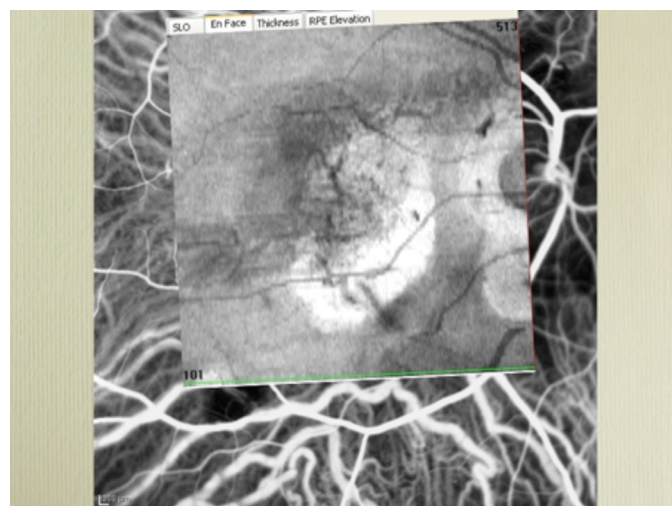


Figure 2. En Face OCT images

Finally, we have Non-Invasive Microvascular Enhanced Imaging, and there are multiple approaches with this technology as well: phase variance, phase contrast, and split-spectrum amplitude-decorrelation angiography (SSADA). One of the first descriptions of this technology on phase variance was from Scott Fraser's group in California. <sup>2</sup> They reported the advantages of phase variance OCT-A as allowing "not only noninvasive visualization of a two-dimensional retinal perfusion map but also volumetric morphology of retinal microvasculature with high sensitivity." <sup>3</sup> This imaging technique takes three B-scans at the same position, aligns them in an axial direction, calculates the average intensity and phase changes, then moves onto phase variance calculation. But taking something from the lab to clinic is not always possible. Optovue AngioVue image system use high speed scan SD-OCT, SSADA algorithm, and Motion Correction technologies solved the practical clinic use issue.

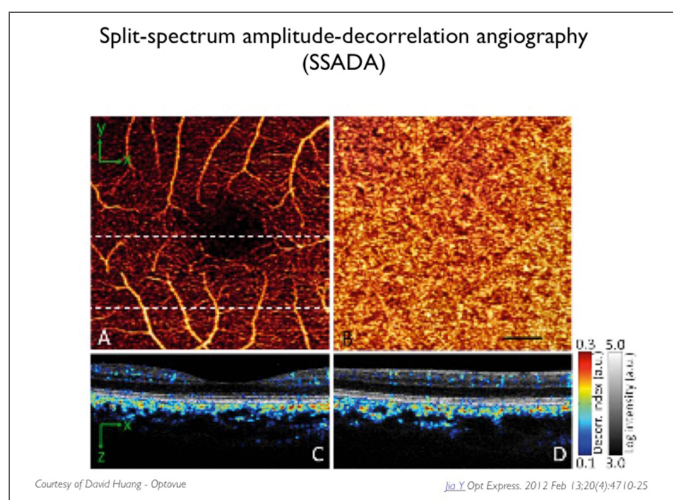


Figure 3. AngioVue images

## Improving visualization with the AngioVue Imaging System

In the earlier days of retinal imaging, each iteration brought a little bit better quality of images, so retinal disorders such as occult lesions, polypoidal lesions, or retinal vessel changes could be seen. But moving from fluorescein and ICG to angiography, there was still an issue of “noise” that did not allow for the contrast we would like to have.

The Optovue AngioVue Imaging System, however, provides exquisite imaging (see Figure 3).

As software has improved, it is becoming clear that OCT angiography is substantially better than ICG if you’re looking at just a single frame. This latest software improvement on the AngioVue Imaging System leaves little room for debate. The vasculature is well defined (see Figure 4).

As the software continues to improve, the images we take will be even more in-depth. I’m looking forward to incorporating the Optovue technology into my imaging armamentarium.

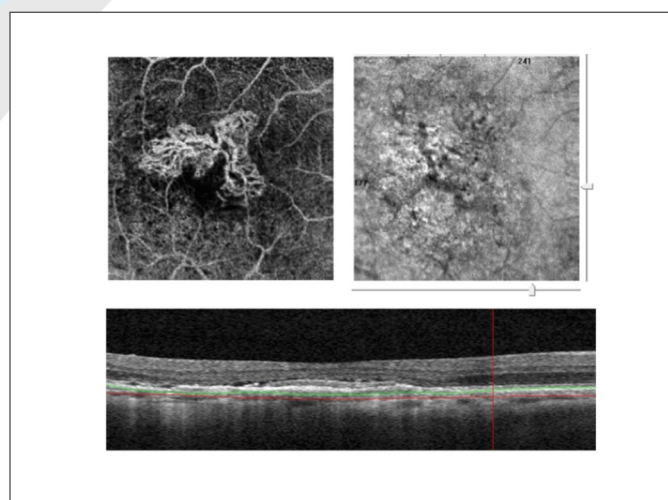


Figure 4. AngioVue images of newly formed neovascularization lesions

## References:

1. Choi W, Mohler KJ, Potsaid B, et al. Choriocapillaris and choroidal microvasculature imaging with ultrahigh speed OCT angiography. PLoS One. 2013;8(12):e81499.
2. Fingler J, Zawadzki RJ, Werner JS, et al. Volumetric microvascular imaging of human retina using optical coherence tomography with a novel motion contrast technique. Opt Express. 2009;17(24):22190-200.
3. Kim DY, Fingler J, Werner JS, et al. In vivo volumetric imaging of human retinal circulation with phase-variance optical coherence tomography. Biomed Opt Express. 2011;2(6):1504-13.

*Prof. Giovanni Staurenghi, presently Professor of Ophthalmology at the European School for advanced Studies in Ophthalmology, is Chairman of the University Eye Clinic and Director of the University Eye Clinic Department of Biomedical and Clinical Scienze “Luigi Sacco” at “Luigi Sacco Hospital in Milan Italy. He may be reached at giovanni.staurenghi@unimi.it*



# Macular Pathologies and OCT Angiography

*Subtleties in the vascular architecture are readily seen on the AngioVue Imaging System*

By Yasushi Ikuno, MD



**T**he AngioVue Imaging System is an optical coherence tomography based system that detects the vascular flow of the retina and the choroid. I have just recently begun using the system, and I will concentrate on discussing how this system differs from other imaging devices.

First, the initial key data window of the system shows the vascular flow of the retinal surface, deep retina, outer retina and choroid at various scan sizes. At both the 6x6 mm and 3x3 mm scan levels, the Angioflow images are capable of clearly imaging the vessels, but for a truly detailed observation, we recommend using the 3x3 mm scans.

However, especially as the clinician is getting familiar with the system, I recommend using the 8x8 mm scans as well. They can give more of an overview, will make it easier to differentiate between this system and fluorescein angiography (FA), and the images are particularly helpful, especially in the larger pathologies. The smaller the scan size, the more detailed the images.

In my experience, some darker spots captured on the 8x8 mm scans are not necessarily there when we go one level deeper to the 6x6 mm scans. In Figure 1, the orange circle on the 8x8 mm scan is indicative of a non-perfusion area, but when that same area is imaged at 6x6 mm (middle image) there's now an additional area of potential concern (the yellow circle). Getting to the most detailed image, the 3x3 mm scan, confirms the questionable non-perfusion area was not, and what was initially thought to be non-perfusion on the 8x8 mm scan was both non-perfusion and tortuous (right image).




Figure 1. An overview of the SSADA based AngioFlow image with images at various scan sizes

We are currently targeting on vascular diseases such as branch and central retinal vein occlusion, diabetic retinopathy and maculopathy, and age-related macular degeneration. Other diseases include retinal angiomatous proliferation, Vogt-Koyanagi-Harada disease, and central serous chorioretinopathy.

## Case studies

In one case that nicely illustrates the advantages of the AngioVue Imaging System over FA, a 71-year-old male with branch retinal vein occlusion presented with an obstructed vessel at the supero-

temporal side. FA picked up the non-perfusion area, as shown on the left image with the blue arrowheads (see Figure 2). There are some key differences between what an abnormality looks like on FA and what it does on the AngioVue, and clinicians need to familiarize themselves with these differences to ensure they are not misidentifying or misdiagnosing.

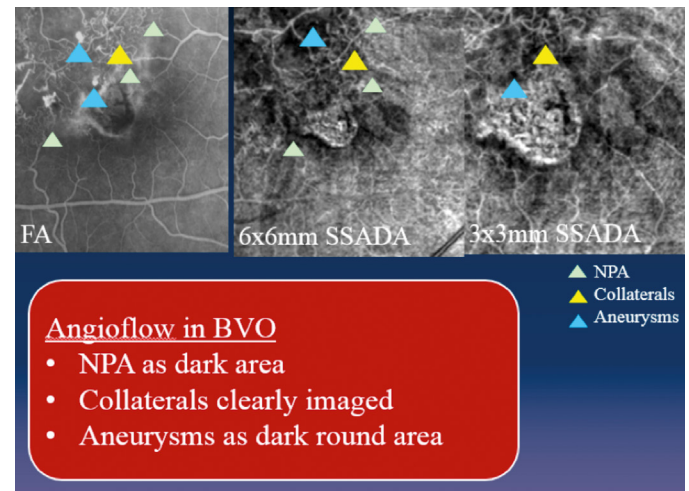


Figure 2. Comparative images of fluorescein angiography and Angioflow

In this case, we used the AngioVue Imaging System, and carefully compared the results with the FA images. There are a couple of things of note. One is, again, the non-perfusion area. Angioflow images will show it as a dark area, with no capillary field, and it corresponds well to what we're used to seeing on FA (see Figure 2). It's important to note the collaterals that are developing on the FA image, but they can also be seen on AngioVue images as well. Aneurysms present as darkened round areas, an obvious difference

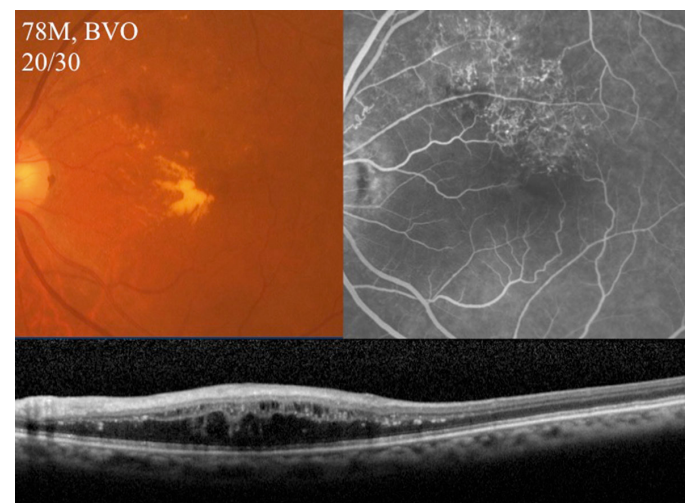

Figure 3. Typical presentation of branch retinal vein occlusion




Figure 4. Same patient, imaged with FA and AngioVue

from regular vessels. In this case, the 6x6 mm scan provided equally useful information as the 3x3 mm scan.

So I think the advantage of the AngioVue system in this patient is with both the non-perfusion area and the collaterals, which are of better quality than we were able to obtain with FA. We also

found normal vascular architectures in the nasal area that the FA was unable to image well.

In another case of branch retinal vein occlusion (see Figures 3 and 4) a 78-year-old male presented with 20/30. As Figure 3 shows, the typical presentation of BRVO, hemorrhages, and the exudates. The collaterals are obvious on FA, and in this case, the hyper signals are also visible on FA, probably leaking from damaged vessels or perhaps a macular aneurysm. Figure 4 shows the comparison between the FA and the AngioVue images. Again, note the AngioVue images shows the nonperfusion area (temporal to superior) as a darkened area, but also note how much clearer the capillary dropout behind the leakage is on 3x3 mm AngioVue.

In summary, the AngioVue Imaging System produces beautiful retinal images, but there is a learning curve associated with the device. It's useful when detailed retinal vascular structures are necessary to confirm a diagnosis. And the positive Angioflow images, such as capillaries and collaterals, are very agreeable with FA. However, how to interpret these images is an ongoing discussion.

*Yasushi Ikuno is associate professor, Department of Ophthalmology, Osaka University Medical School and is in the Division of Ophthalmology, Osaka National Hospital, Osaka, Japan. He may be reached at [ikuno@ophthal.med.osaka-u.ac.jp](mailto:ikuno@ophthal.med.osaka-u.ac.jp)*

## Imaging the Optic Disc with OCT Angiography

*New Optovue device enhances the way we view glaucoma patients*

By Michel Puech, MD, FRCS



**T**he split-spectrum amplitude decorrelation angiography (SSADA) proprietary software on the AngioVue Imaging System (Optovue) is a completely new way of analyzing blood flow inside retinal vessels based on optical coherence tomography (OCT) technology, without the use of contrast agents and without injection of fluorescein or indocyanine green.

Studies have commented on the advantages of using OCT-Angiography (OCT-A) to detect blood flow; Jia et al. said the high resolution of OCT-A lends itself to 3D, but that it is less sensitive to the flow signal. SSADA improves the signal-to-noise ratio of flow detection and overcomes the majority of the earlier issues.<sup>1</sup>

With SSADA, we don't have just an angiography system. We have, instead, a deep penetration system and a higher resolution system that allows us to clearly identify portions of the optic nerve that were previously unavailable to us.

This new technology will allow us to have enhanced imaging in several diseases, including age-related macular degeneration and glaucoma. Too few clinical trials analyze the optic disc, but this technology may help change that. At our clinic, we were surprised by ability of this system to visualize and separate the outer and inner vascular network of retina. Using the AngioVue to image the optic nerve head, we were very surprised to observe a particularly dense vascular network around the disc. In fact, we can see a very dense vascular network around

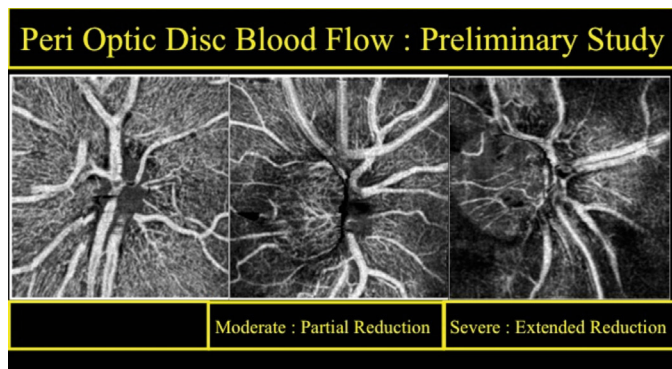
the disc that we were not able to detect with fluorescein angiography. This network is located superficially just underneath the fiber optic layer or mixed with the fibers. We believe those vessels have a role in nourishing the fibers. We were surprised, however, to find a clinical correlation between glaucoma stage and reduction of this superficial vascular network around the disc.

For example, in cases of advanced glaucoma this vascular network seems to be in extremely poor condition, whereas in cases of moderate glaucoma, only a few quadrants seem to have vascular reduction.

### Initial studies show promising results for glaucoma management with AngioVue Imaging System

A preliminary study using OCT-A evaluated the peripapillary disc blood flow in 39 patients (78 eyes). At baseline, patients underwent visual field testing, retinal nerve fiber layer and ganglion cell evaluations. Patients were divided into three groups (no glaucoma, moderate, advanced) based on the baseline imaging. Then peripapillary disc blood flow was analyzed, with normal being no reduction, moderate being partial reduction, and severe being extended reduction. Figure 1 shows examples of the three levels. Our initial results found good correlation between the peripapillary disc blood flow and the levels of

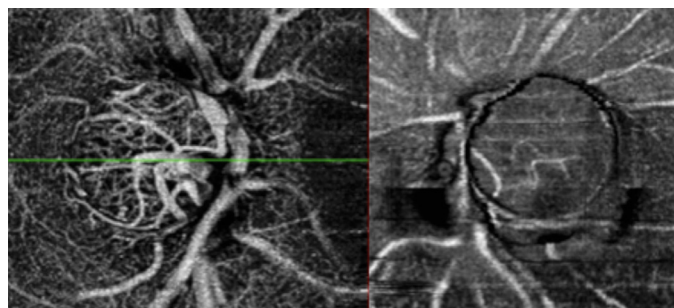




**Figure 1.** Peri optic disc blood flow. The left image shows a patient with no glaucoma evidence: notice a very dense vascular network around the disc. The center image shows moderate glaucoma with clear reduction of vascularization around the disc but only on the temporal inferior quadrant. The right image shows advanced glaucoma with extended reduction of vascular network all around the disc

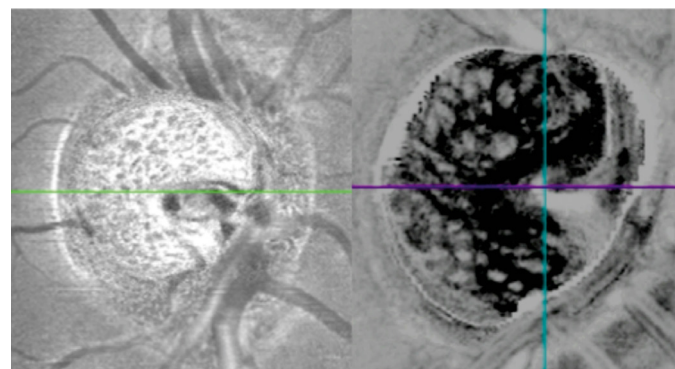
glaucoma, but we do caution that this is a preliminary study and does have some subjective biases.

The second part of our study concentrated on analyzing the blood flow inside the disc. The AngioVue Imaging System allowed us to observe a multitude of vessels in a normal patient (no glaucoma). I had previously thought the center of the optic disc would only contain fibers. Yet we now observe that the vessel layer is uniform both externally and internally in relation to the disc in healthy eyes. With this system, we can see the reduced vascularization inside the disc in glaucoma patients when compared to patients without glaucoma. However, we will need to enroll larger numbers of patients to ascertain what, if any, clinical relevance there is between vessel size and glaucomatous damage (Figure 2).



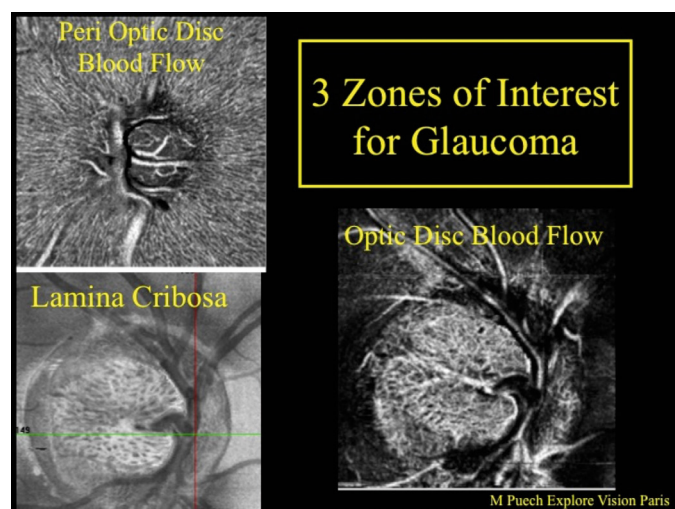
**Figure 2:** Left: Angioflow images show a dense vascular network inside the disc, but no evidence of glaucoma. Right: Angioflow images show advanced glaucoma with very poor vascular network inside the disc and around the disc

In a third area of study, we are using the AngioVue Imaging System to evaluate the lamina cribrosa. The increased resolution of this system allows us to better visualize the pores. We were surprised to observe various pore shapes on the lamina cribrosa; many patients have “regular” pore shape, but we observed both enlarged and stretched pores. Further study will be necessary to determine if a correlation with glaucomatous damage exists. (Figure 3)



**Figure 3:** The left image shows pores as seen with the AngioVue system. On the left with inverted contrast image, pores can be enlarged or stretched

In my opinion, the incredible ability of the AngioVue Imaging System as applied to the vascular network analysis, both around and inside the disc, coupled with the system's ability to visualize lamina cribrosa pores, has convinced me that this new tool will take an important place in glaucoma patient follow-up, and in understanding glaucoma physiopathology (Figure 4).



**Figure 4.** There are three zone of interest for glaucoma analysis with AngioVue imaging system: vascular network, around and inside the disc, and lamina cribrosa pores

## Reference:

1. Jia Y, Tan O, Tokayer J, et al. Split-spectrum amplitude-decorrelation angiography with optical coherence tomography. Opt Express. 2012;20(4):4710-25

Dr. Puech is the manager of Explore Vision Paris and Explore Vision Rueil, and an instructor at VuExplorer Institute. He may be reached at [m-puech@orange.fr](mailto:m-puech@orange.fr)

# Optovue Imaging Device Offers Great Potential for Anterior Segment Imaging

*The device's ability to image both the anterior and posterior cornea helps provide more accurate IOL calculations, among other things*



By Douglas D. Koch, MD

**T**he RTVue Premier (Optovue) is the first Food and Drug Administration-cleared OCT device that has approval for both corneal and retinal imaging. While most clinicians are familiar with OCT for its retinal capabilities, the ability of this device to scan the cornea out to 6mm and scan both the front and the back of the cornea may be underappreciated. Standard topography only calculates the front curvature and then extrapolates posterior curvature. But the RTVue can actually calculate mean corneal power by taking into account front and back curvatures and corneal thickness. The "Total Corneal Power" module enhances post-refractive IOL calculations, helping to improve surgical outcomes.

OCT in general is literally exploding in the range and quality of new applications. The engineering details base the design on interferometry performed over a wide spectrum and has some of the best quality resolution.

We've worked with David Huang, MD, PhD, at the Center for Ophthalmic Optics and Lasers in Portland, Oregon, (COOL, [www.coollab.net](http://www.coollab.net)) to provide him with data from our site to assist his team in developing an RTVue-based formula for calculating IOL power in eyes that have undergone myopic and hyperopic LASIK (see Figure 1).<sup>1,2</sup> Although the formula is not intended for patients with previous radial keratotomy or for those who have never undergone laser vision correction, for patients with previous LASIK, the formula has been quite accurate. Compared with other formulas, this one has a slightly lower median absolute error and a higher percentages of patients within 0.5 D to 1 D postoperatively than with other formulas. These are small differences, but it certainly puts this calculator in the league among the best formulas. We have plans to put this up on the ASCRS website as well, but it's currently available for download at <http://coollab.net/index.php?id=852>

## Other anterior segment capabilities

Using Fourier-domain technology on the RTVue, our group published a paper evaluating healing changes in clear corneal cataract incisions to characterize the types of healing patterns at various stages postoperatively.<sup>3</sup> In that study, we obtained multiple OCT images and used it to measure the incision midpoint. We found Descemet membrane detachment in 37% of the eyes at postop Day 1, posterior wound gape in 86% of eye at postop Day 1, both of which persisted for up to 3 months. Posterior wound retraction developed later, but persisted in more than 90% of the eyes after 3 years. We're currently using the device to look at intrastromal corneal relaxing incisions made with a femtosecond laser during cataract surgery to correlate those incisions with the topographic and astigmatic changes that occur.

The Optovue system excels at detecting subtle changes in Descemet's membrane (eg, low detachments), and we've found it helpful in evaluating corneal opacities. For anterior segment surgeons, it's a useful diagnostic tool for confirming a suspicion that there might some fluid in the interface of the cornea and for

diagnosing a patient whose pressure might be high. There are a substantial number of other clinical applications as well.

One fascinating new application has been pioneered by my colleague Stephen C. Pflugfelder, MD. He has found RTVue imaging of the tear meniscus to be very helpful in diagnosing dry eye disease. He also uses it to assess the impact of conjunctivochalasis on tear flow.

The RTVue's ability to provide full thickness corneal measurements can also help us screen potential laser vision correction candidates better as well. Measurements of overall thickness aid in detecting mild keratoconus, but epithelial measurements are now quite sensitive for detecting forme fruste keratoconus.

The Optovue system is now also helping monitor epithelial healing after LASIK and PRK, and we feel that it will help us better understand some under- and overcorrections that occur.

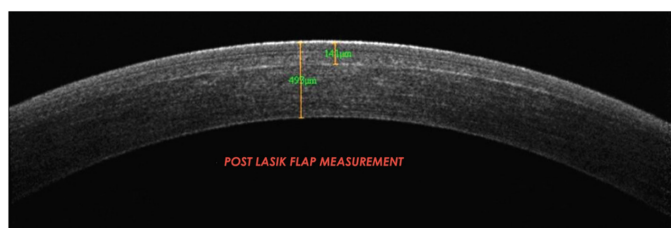


Figure 1. Imaging a post-LVC patient

*The Optovue RTVue is capable of imaging both the anterior and posterior cornea, so calculating IOL powers in a post-laser vision correction patient is more accurate*

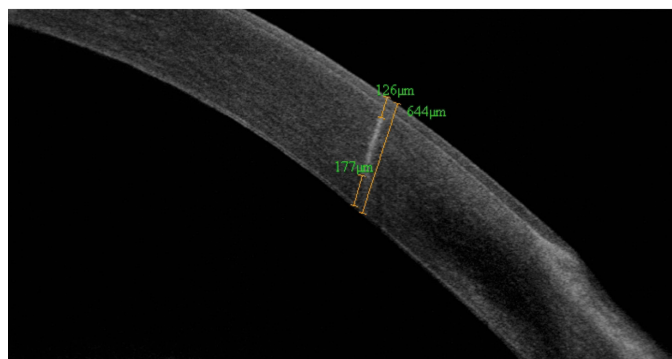

Figure 2. Image of intrastromal relaxing incision

*RTVue image and measurements of an intrastromal relaxing incision made during cataract surgery*

## Improving technology

Optovue has developed a new device XR-Avanti that will operate almost 2.5 times quicker than the current version. The newer iteration will have the ability to capture more scans per second, and may be able to provide better data as a result. My hope is that it will have improved accuracy for calculating total corneal power and that it will provide a means for measuring posterior corneal astigmatism.

Image courtesy of Optovue

Image courtesy of D.D. Koch, MD



## References:

1. Tang M, Wang L, Koch DD, Li Y, Huang D. Intraocular Lens Power Calculation after Myopic and Hyperopic Laser Vision Correction Using Optical Coherence Tomography. Saudi Journal of Ophthalmology. 2012;26:19-24.
2. Tang, M Wang L, Koch DD, Li Y, Huang D. Intraocular Lens Power Calculation after Previous Myopic Laser Vision Correction Based on Corneal Power Measured by Fourier-Domain Optical Coherence Tomography, J Cataract Refract Surg. 2012;38(4):589-94.
3. Wang L, Dixit L, Weikert MP, Jenkins RB, Koch DD. Healing changes in clear corneal incisions evaluated using Fourier-domain optical coherence tomography. J Cataract Refract Surg. 2012;38(4):660-5.

*Douglas D. Koch, MD, is a professor and the Allen, Mosbacher, and Law chair in ophthalmology at the Cullen Eye Institute of the Baylor College of Medicine in Houston. Dr. Koch may be reached at (713) 798-6443; [dkoch@bcm.tmc.edu](mailto:dkoch@bcm.tmc.edu)*

