

# Advanced Imaging Technology Enhances Pediatric Ophthalmology Practice

SD-OCT case reports.

BY STEPHEN B. PREPAS, MD

Since I first acquired a spectral-domain optical coherence tomography (SD-OCT) device in my pediatric ophthalmology practice, this mode of imaging has become a standard diagnostic tool. Also known as fourier-domain OCT, the technology has a much higher quality of image than the previous standard of care, time-domain OCT. These new machines scan 65 or more times faster than the older OCT images, and registration is based on ocular structures rather than patient fixation. The improvement in image quality and clarity is outstanding. The 3D profiles of retinal layers have proved a substantial aid in the diagnosis and tracking of a variety of pathologies.

In my practice, I use the iVue (Optovue, Fremont, CA), which is the compact version of the RTVue SD-OCT but with the same imaging quality as the RTVue. It offers the same scanning speed and resolution as the larger system that includes scanning and reports for retina, retinal nerve fiber layer and cornea assessment by the clinician, but with a smaller footprint and streamlined user interface. For a pediatric ophthalmologist, fast and efficient clinical use, compact size, and portability are all important.

Aside from the technology's ability as an aid in diagnoses, I find another benefit of using SD-OCT is the ability to share the image with the patient and the family. So much of what we tell our patients about their ocular health is abstract; they cannot see pathologies of the eye through the slit lamp as they can see a broken bone on an x-ray. Being able to show them an OCT image, however, has significantly aided my patients' and their families' understanding of the conditions that affect vision.

So much of what we tell our patients about their ocular health is abstract; they cannot see pathologies of the eye through the slit lamp as they can see a broken bone on an x-ray.

## CASE #1

My first case involves a sister and brother, aged 4 and 10 years. The 10-year-old boy had previously been diagnosed with vitelliform macular dystrophy, better known as Best disease, and was coming in for a checkup. While he was there, the patients' mother requested that the 4-year-old girl be checked at the same time. She stated that there had been no manifestations of vision problems with the 4-year-old, and she had not had a vision exam. However, she felt there might be a similar pathology. Best disease is an autosomal dominant disorder that classically presents in childhood with the appearance of a yellow or orange yolk-like lesion in the macula. I examined the daughter and, unfortunately, saw early changes in the macula that indicated she had the same pathology as her brother.

At the time, I did not have an OCT device, so I referred them to a retina specialist to ensure that the mother was getting the best information for her children. The retina specialist confirmed my diagnosis of Best disease and examined the boy with OCT technology but declined to scan the girl due to her young age.

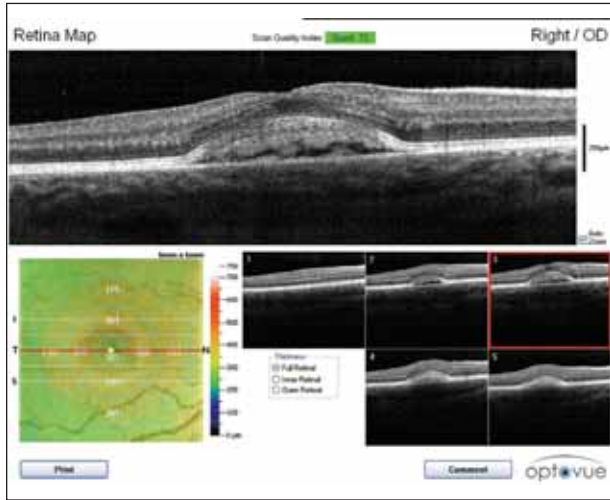


Figure 1. Best disease in 4-year-old eye (OD).

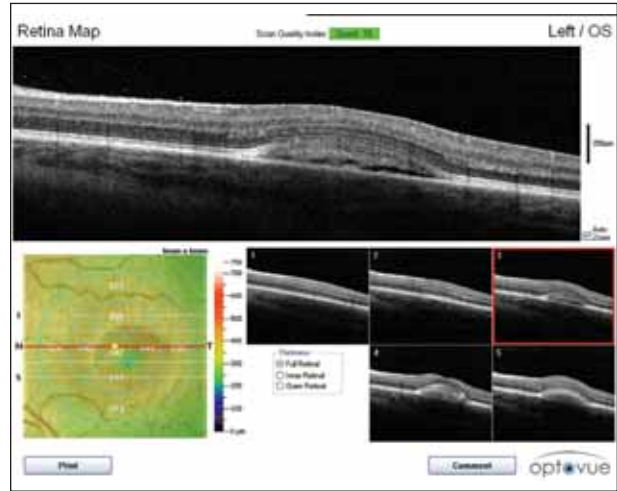


Figure 2. Best disease in 4-year-old eye (OS).

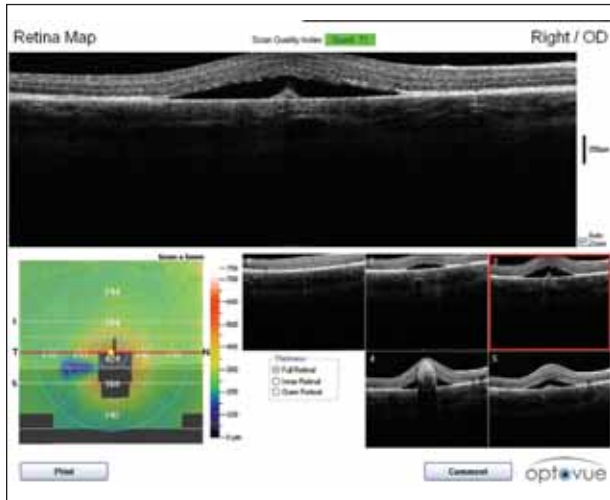


Figure 3. Best disease in 10-year old eye (OD).

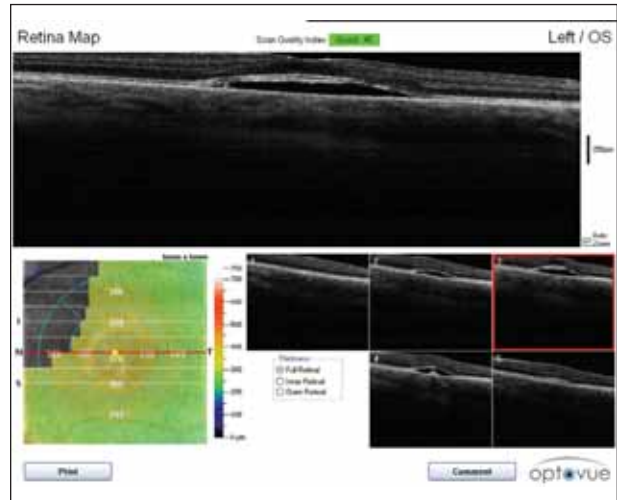


Figure 4. Best disease in 10-year-old eye (OS).

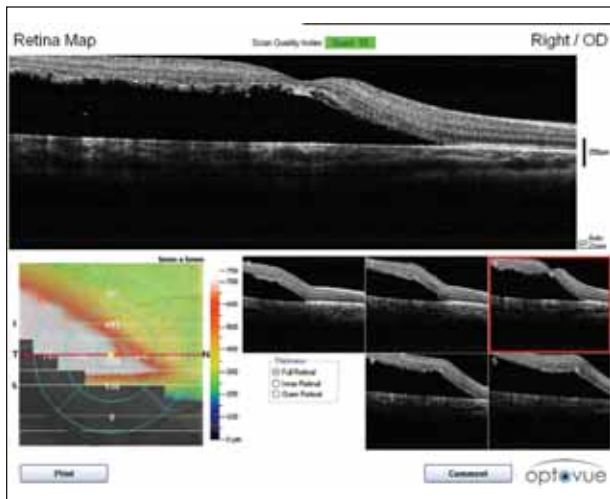


Figure 5. Retinal detachment in 11-year old eye (OD).

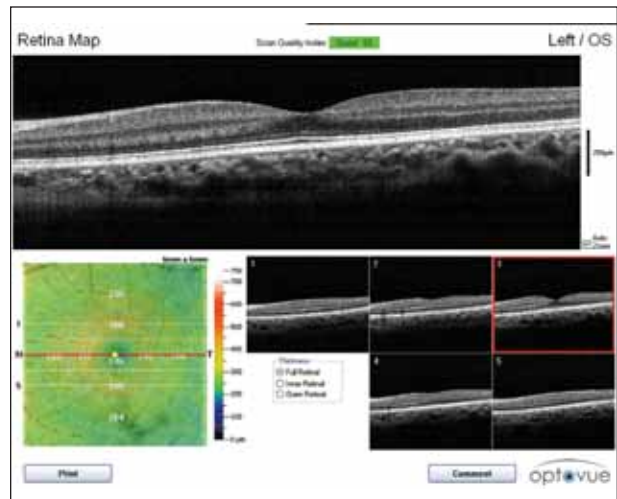


Figure 6. Normal 11-year-old eye (OS).

# Portable Spectral-domain OCT: A New Way of Looking at the Eye

BY NALIN J. MEHTA, MD

Spectral-domain (SD) OCT has quickly become a standard of care in ocular diagnostics. Three-dimensional images of structures such as the cornea, retina and optic nerve are becoming essential in the analysis and management of a variety of pathologies. The iVue (Optovue, Fremont, CA) is a compact, portable SD-OCT unit used for both corneal and retinal imaging. When combined with the iStand, a mobile floor stand recently approved by the US Food and Drug Administration, the iVue is able to scan patients in a variety of positions, including prone, supine, and lying on the left or right side.

I have had the opportunity to investigate both immediate and potential applications of the iVue with iStand (Figure 1) in my retinal practice. These include:

The ability to image patients that may not be able to sit up and position themselves properly in front of a conventional OCT instrument. As the population ages, for example, so does the number of physically invalid patients that may have orthopedic problems that prevent them from sitting erect. The iVue with iStand allows much more versatile OCT positioning in these patients. These principles are of course applicable in other age groups as well.

In surgical management of macular pucker and macular hole, evaluation of the macula immediately after epiretinal or internal limiting membrane removal with the iVue with iStand in these cases can identify residual tractional

membranes, potentially eliminating the need for off-label, potentially toxic surgical adjuncts such as indocyanine green. This can in turn theoretically reduce reoperations, with associated morbidity and costs. In addition, minute iatrogenic holes can be detected and managed intraoperatively.

Perioperative evaluation during complex retinal detachment surgery with proliferative vitreoretinopathy, particularly under perfluorocarbon liquid or silicone oil, may allow the surgeon to assess the pre- and subretinal spaces for residual traction, which may require additional membranectomy.

Footpedal image acquisition allows the surgeon to simultaneously position and stabilize the patient's head during imaging and to operate the iVue's keyboard for real-time patient data

input and analysis. This feature simplifies use for the physician with minimal staffing.

The advent of portable SD-OCT introduces the retinal specialist to diagnostic possibilities that can only serve to enhance the surgeon's diagnostic acumen and improve patient outcomes.

*Nalin J. Mehta, MD, is in private practice at Colorado Retina Center in Denver. Dr. Mehta is a consultant and speaker for Optovue, Inc. He can be reached at +1 303 893 5138; or via email at fovea1@comcast.net.*

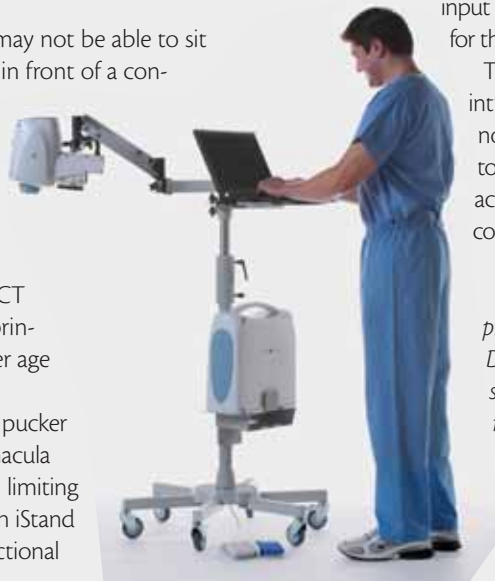

Figure 1. The iStand.

When I got the iVue SD-OCT in my practice, I called the mother back and asked her to bring in her children for follow-up exam. This small, portable machine made the exam very simple and nonthreatening for the children, and I was easily able to examine both children. After I had scanned the children's eyes, I made a point of showing the images (Figures 1-4) to the mother, along with a comparison image of a healthy eye. With the images in front of her, she was quickly able to see the excess tissue in her children's eyes. After years of talking in abstract terms and hearing things like "incorrect formation of the retina" and "structural problems

with the macula," she finally had a concrete understanding of the disease.

Unfortunately, there is no cure for Best disease. However, it was clear that the ability to view the pathology made it understandable to the mother and had a positive impact on the physician-patient relationship. Telling parents that their children have an incurable disease that will leave them with poor vision is never a welcome moment. Because the mother already anticipated the situation and I had images to share with her, this helped her to understand the situation more clearly and improved the patient-physician relationship at the same time.

**CASE #2**

My second case is that of a boy aged 11 years who reported at presentation that he had experienced deteriorating vision in his right eye over the past month. A visual exam confirmed that he was seeing 20/20 in his left eye and 20/400 in his right eye. His refraction was asymmetric, and I was leaning toward a diagnosis of amblyopia or lazy eye, assuming the patient was incorrect with his statement that his vision had been poor for only the last month. On dilated exam, the left eye looked normal, but the right eye seemed to have a slightly duller reflection and did not appear healthy, although I was unsure why. I decided to use SD-OCT to check for further pathology, and upon examination with OCT I could clearly see a large, albeit shallow, retinal detachment.

In most retinal detachment cases, the sub-retinal space fills with fluid and the retina becomes very edematous, making it difficult to get a good refraction. In place of a red color, one often sees grey. However, in this case, the detachment was so shallow that the refraction showed slightly hyperopic and the red reflex remained. Had I not had access to SD-OCT, I would have referred the patient to a retina specialist without being able to make a definitive diagnosis.

In addition to aiding with the diagnosis, I was able to show the SD-OCT image of the retinal detachment (Figure 5) to the patient and his mother against that of a normal scan (Figure 6). They were able to see that there was an anatomic pathology and understand the urgency in getting to the retina specialist right away. In this particular case, the iVue enabled me to make the correct diagnosis and communicate the pathology to the patient.

**SUMMARY**

Speed, resolution, and registration are the 3 most important factors for physicians who rely on OCT imaging. SD-OCT imaging provides the ability to accurately track changes in volume, central thickness, and retinal pigment epithelium height and thickness. This advanced technology allows physicians to discriminate the finer points of pathology and directly affects how they manage treatment. Also important is that SD-OCT produces a high quality 3D image that can be shared with and understood by the patient. In this age of

patient involvement in medical care, these images can go a long way in building the relationship between the physician and patient. ■

*Stephen B. Prepas, MD, is a pediatric ophthalmology and strabismus doctor in Newport Beach, CA. He reports no financial interest in the products mentioned in this article. Dr. Prepas can be reached at +1 949 644 7026; or via email at sbprepas@gmail.com.*



**ADVANCED RETINAL THERAPY**  
UPDATE – TRENDS – CONTROVERSIES

Vienna, Saturday, December 3rd, 2011

**Don't miss it – register today**

**Scientific Program**

- State-of-the-Art Diagnostics in Retina
- Intravitreal Therapy: An update for the clinician
- Update in Vitreoretinal Surgery

**Social Evening Program**

- Classic concert and Gala Dinner

Details and registration: [www.artvienna.eu](http://www.artvienna.eu)

Location of Scientific Program:  
Österreichische Akademie der Wissenschaften  
Dr. Ignaz Seipl-Platz 2, 1001 Vienna, Austria